

The Role of Cimetidine-Enhanced Technetium-99m-Pertechnetate Imaging for Visualizing Meckel's Diverticulum

Case Presentation and Discussion: Robert H. Diamond, Robin D. Rothstein, and Abass Alavi

From the Case Records of the Hospital of the University of Pennsylvania, Philadelphia, Pennsylvania

J Nucl Med 1991; 32:1422-1424

CASE REPORT

A 33-yr-old white male postal worker was admitted because of gastrointestinal bleeding. He was in good health until 2 mo prior to the current admission when he presented at a community hospital with a 24-hr history of maroon stools. On admission he was orthostatic and tachycardic. His physical exam was otherwise unremarkable except for maroon stool on rectal examination. A nasogastric aspirate was bilious and negative for blood. The initial hemoglobin level was 10.0 g/dl, but subsequently fell to 8.1 g/dl. He was transfused with two units of packed red blood cells. A diagnostic work-up, including upper endoscopy, colonoscopy, ^{99m}Tc-tagged red cell scan and ^{99m}Tc-pertechnetate Meckel's scan, was negative. The bleeding stopped, and he was discharged with instructions to take iron supplements.

The patient did well until 2 mo later when he again presented to the same hospital with maroon stools, orthostatic hypotension, and a hemoglobin of 9.0 g/dl. Work-up included a nasogastric aspirate, which was again bilious and negative for blood. In addition, endoscopy, which included the duodenum down to the ligament of Treitz using a pediatric colonoscope, was also negative. Colonoscopy to the terminal ileum revealed no abnormalities, but blood was observed to be coming from above. The patient's bleeding continued, and despite the transfusion of four units of packed red blood cells, his hemoglobin fell to 6.7 g/dl. An upper gastrointestinal with small bowel follow-through examination was unremarkable. Soon thereafter, the patient passed a large amount of bright red blood per rectum and became hypotensive. He was transfused with an additional two units of packed red blood

cells and was transferred to the Hospital of the University of Pennsylvania for further evaluation.

Upon admission, there was no evidence of active gastrointestinal bleeding. Physical exam was notable for orthostatic hypertension, with a supine blood pressure of 130/70 mmHg and a pulse rate of 100/min, which changed on standing to 100/50 mmHg and 120/min, respectively. Abdominal exam was negative except for hyperactive bowel sounds. Rectal exam revealed melena. The rest of his physical exam was normal. He denied medications, including aspirin or similar drugs, or excessive alcohol ingestion. Laboratory data revealed a hemoglobin of 7.8 g/dl, and normal white blood cell count, platelet count, coagulation profile, electrolytes, and liver function tests.

The patient had no further episodes of gastrointestinal bleeding. An abdominal visceral angiogram, performed to search for arterialvenous malformations as a cause for hemorrhage, was negative. Following this, a [^{99m}Tc]pertechnetate Meckel's scan was performed. The patient had been receiving continuous intravenous cimetidine at a rate of 50 mg/hr for the previous 48 hr and, in addition, received 300 mg of intravenous cimetidine 30 min prior to the exam. An area of accumulation of radiotracer was noted in the mid-lower abdomen that was consistent with the diagnosis of Meckel's diverticulum (Fig. 1). The patient was taken to the operating room the following day, where a 3-cm long Meckel's diverticulum 60 cm above the ileocecal valve was found. The diverticulum was resected, and the patient had an uneventful postoperative course. Pathologic examination of the diverticulum revealed an area of gastric mucosa containing a large number of parietal cells within the Meckel's diverticulum. The patient has remained free of gastrointestinal bleeding 1 yr later.

DISCUSSION

Prior to the introduction of [^{99m}Tc]pertechnetate scanning in 1970, the diagnosis of Meckel's diverticulum was often difficult, with surgery frequently required to establish the correct diagnosis (1). Today, the use of radionuclide

Received Apr. 3, 1991; accepted Apr. 3, 1991.

For reprints contact: Dr. Alavi, Department of Radiology, University of Pennsylvania, 34th and Spruce Streets, Philadelphia, PA 19104.

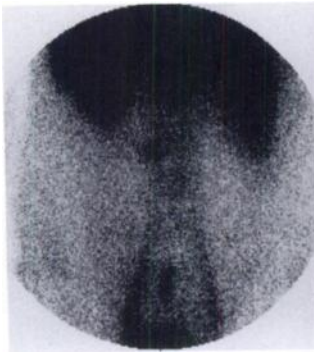


FIGURE 1. An intense focal accumulation of tracer is seen in the midline right above the bladder area 30 min after injection of [^{99m}Tc]pertechnetate. This was interpreted to be consistent with a Meckel's diverticulum.

imaging employing the [^{99m}Tc]pertechnetate Meckel's scan has made this diagnostic work-up less difficult, but it is still a significant challenge. This patient with persistent severe lower gastrointestinal bleeding initially had a negative Meckel's scan. A repeat scan after cimetidine infusion was consistent with a Meckel's diverticulum, and this finding was confirmed at surgery. A review of the literature in this area emphasizes the importance of using cimetidine in conjunction with Meckel's scanning to increase the diagnostic yield of the procedure.

In 1933, Charles Mayo wrote that "Meckel's diverticulum is a diagnosis that is frequently suspected, often looked for, but seldom found" (2). Since that time, better diagnostic methods have been developed, but it often remains an elusive diagnosis, especially in adults.

Meckel's diverticulum results from failure of the omphalomesenteric duct to obliterate. When a human embryo is 3 wk old, a portion of the yolk sac gives off this duct in the form of a stalk which then expands to form the future ventral aspect of the gut. In approximately 2% of the population, this duct fails to close in the usual manner by the fifth week of gestation. This results in a persistence of tissue that is usually attached within 2 ft of the ileocecal valve, and in 80% of cases is less than 2 in. long. These lesions are true diverticuli, containing all layers of the intestinal wall, and can contain gastric, pancreatic, duodenal, jejunal, or even colonic mucosa. There is a 2:1 male/female incidence of this malformation, and 50% of those that become symptomatic will do so before the age of 2 yr (3).

The percentage of Meckel's diverticula that eventually become symptomatic is unclear. Johann Meckel, who described the anomaly in 1812, felt this to be approximately 15%, and this number has been commonly cited in the literature.

Gastrointestinal bleeding is the most common clinical manifestation of Meckel's diverticulum in patients younger than 40 yr, especially in the pediatric age group (4). Bleeding is usually brisk, presenting with hematochezia and hypovolemia, but it can also present with melena or, rarely, with occult blood loss. Bleeding from a Meckel's diverticulum after age 40 is unusual, although a case has been reported in a 93-yr-old man (2). When bleeding

occurs, it is almost always in a Meckel's diverticulum with ectopic gastric mucosa. While only 15% of Meckel's diverticula have gastric mucosa, 95% of those that present with bleeding have gastric mucosa. Hemorrhage is felt to be due to adjacent ileal ulcers brought about by local effects of the acid produced by the ectopic gastric mucosa (2).

Other clinical manifestations are more commonly seen in adults and include diverticulitis and intestinal obstruction. A Littre's hernia is an inguinal hernia that contains a Meckel's diverticulum. Once a Meckel's diverticulum has been established as the cause of a clinical syndrome, the treatment is surgical resection of the diverticulum(2,3).

Until the introduction of [^{99m}Tc]pertechnetate scanning, the diagnosis of Meckel's diverticulum was quite difficult since the two tests most commonly available at that time, small bowel follow-through x-rays and angiography, were inappropriate tests in many patients. Meckel's diverticula are often not identified on small bowel follow-through films because they are not well filled and have rapid emptying since they have a full muscular coat (5). In addition, the ostium of the diverticulum may be narrow and stenotic, so barium may not enter it at all, although the diverticula are characteristically wide-mouthed. Meguid described a series of 33 consecutive patients with surgically-proven Meckel's who had negative small bowel follow-through examinations prior to surgery, and he concluded that the use of this study for the diagnosis of Meckel's diverticulum should be abandoned (4). Small bowel enteroclysis is felt to be a better test than simple small bowel follow-through since the higher pressure of the barium column more reliably fills the diverticulum and has been reported to have a sensitivity as high as 87% (6).

Angiography has never been studied in a systematic manner with respect to the diagnosis of Meckel's diverticulum, but there are several case reports in the literature (7,8). The consensus is that angiography is probably only useful if there is brisk active bleeding that directs the examiner's attention to the proper area. In such cases, one may note a tortuous artery supplying an area of dense capillaries, almost like a "tumor blush," since these vessels are embryonic in origin. However, even in known cases of Meckel's diverticulum, none of these signs may be present. In the present case, the angiogram was read as normal, and once the diagnosis was known, no abnormality could be demonstrated.

Technetium-99m-pertechnetate Meckel's scanning-represented a major advance in the radiologic diagnosis of Meckel's diverticulum. The logic behind the use of the scan is based upon the existence of gastric mucosa in some Meckel's diverticula (3). Technetium-99m-pertechnetate is taken up preferentially by the mucus-secreting cells of the gastric mucosa. After injection of pertechnetate, images are recorded every 5 min for 30 min, then every 15 min

for 1 hr. In patients with Meckel's diverticulum, an ectopic area of tracer accumulation will become apparent, usually in the right lower abdominal quadrant, which parallels accumulation in the stomach. Since the success of the test depends on the presence of gastric mucosa in the Meckel's diverticulum, it is helpful in cases of gastrointestinal bleeding. However, a Meckel's scan has a lower yield for diagnosis of a Meckel's diverticulum presenting with obstruction or inflammation when there is a much lower incidence of ectopic gastric mucosa.

Controversy exists with respect to the reliability of the Meckel's scan as a diagnostic test. Sfakianakis reported a large retrospective review of 954 patients with surgically-proven Meckel's diverticula and found the Meckel's scan to be 85% sensitive and 95% specific (3). Most of the false-negatives were due to an insufficient amount of gastric mucosa in the Meckel's diverticulum. False-positives were due to a variety of causes, including leiomyomas and arteriovenous malformations (felt to "light up" due to their increased blood pool), renal and collecting system cysts and diverticuli (the tracer is excreted by the kidneys), as well as isolated reports of positive tests in Crohn's disease, small bowel lymphoma, carcinoma of the sigmoid, and one case of a bleeding appendiceal stump. The authors noted that many of these conditions would require surgical management anyway, that false-negatives were the biggest problem with the test, and that in general it was quite useful (3).

However, others have noted that most of the patients in Sfakianakis's group were children (more than 90%). Numerous reports exist in the literature of false-negative Meckel's scans in adults (9). In a review of 184 adults with surgically-proven Meckel's diverticula, Schwartz and Lewis found that the Meckel's scan was only 60% sensitive (10). They speculated that the Meckel's scan is probably much more accurate in children because they are likely to have larger areas of gastric mucosa in their Meckel's diverticulum, thus leading them to present at a younger age with gastrointestinal bleeding. Adults are likely to have less or no gastric mucosa in their Meckel's diverticula, leading to presentation with gastrointestinal bleeding at a later age, or presentation with another symptom, and therefore a negative Meckel's scan.

To increase the diagnostic yield of Meckel's scanning in adults, several investigators have worked on modification of the test. In 1978, Treves reported that pre-treatment with pentagastrin increased the rapidity, duration, and intensity of stomach uptake of pertechnetate by 65% and cited a case where a subcutaneous dose of 6 mg/kg of this drug resulted in the conversion of a negative scan to positive. A Meckel's diverticulum was subsequently found at laparotomy (11). The mechanism by which pentagastrin works in this respect is not clear, but it is thought that the increased acid production caused by this hormone leads to increased activity in the mucus-producing cells and, thus, increased tracer uptake. Pentagastrin, however, also

increases intestinal motility, leading to rapid tracer accumulation in the small intestine and, thus, the possibility of false-positive scans. In addition, it is a potent stimulator of acid secretion from the gastric mucosa. Since hemorrhage from Meckel's diverticula is thought to be a result of acid-induced ileal ulceration, it is apparent that the increased acid secretion by pentagastrin might be clinically undesirable.

The use of cimetidine to enhance the sensitivity of Meckel's scanning was first reported by Petrokubi in 1978 (12). Patients were given 300 mg of cimetidine four times a day with an additional 300-mg dose 1 hr before the test. They found that this resulted in more intense and prolonged uptake of the pertechnetate tracer by the gastric mucosa in both the stomach and in Meckel's diverticulum. They reported two patients in whom previously negative Meckel's scans became positive after cimetidine loading, both of whom had surgically-confirmed Meckel's diverticula. The drug is thought to work by blocking secretion from the mucosa, leading to an increased accumulation of tracer. Since that time, other investigators have confirmed the utility of cimetidine in this respect. Cimetidine increases the sensitivity of the test to 90%–95% with no significant risks or side effects (13). No controlled studies have been done to confirm this conclusion, but since the drug is safe and has not been reported to increase the incidence of false-positive scans, it seems reasonable to use cimetidine routinely in Meckel's scanning. Clearly, the diagnosis would not have been made in the case described here without it.

REFERENCES

1. Jewett TC, Duszynski DO, Allen JE. Visualization of Meckel's diverticulum with ^{99m}Tc-pertechnetate. *Surg* 1970;68:567–570.
2. Copland EA, Harolds JA, Taupmann RE. The radiologic diagnosis of Meckel's diverticula. *J Oklahoma State Med Assoc* 1981;74:387–391.
3. Mackey WC, Dineen P. A fifty year experience with Meckel's diverticulum. *Surg Gynecol Obstet* 1983;156:56–64.
4. Sfakianakis GN, Conway JJ. Detection of ectopic gastric mucosa in Meckel's diverticulum and in other aberrations by scintigraphy. *J Nucl Med* 1981;22:647–654, 732–738.
5. Meguid, MM, Wilkinson RH, Canty T, Eraklis AJ, Treves S. Futility of barium sulfate in diagnosis of bleeding Meckel's diverticulum. *Arch Surg* 1974;108:361–362.
6. Maglente DDT, Elmore MF, Isenberg M, Dolan PA. Meckel diverticulum: radiologic demonstration by enteroclysis. *AJR* 1980;34:925–932.
7. Bree RL, Reuter SR. Angiographic demonstration of a bleeding Meckel's diverticulum. *Radiology* 1973;108:287–288.
8. Muroff LR, Casarella WJ, Johnson PM. Preoperative diagnosis of Meckel's diverticulum: angiographic and radionuclide studies in an adult. *JAMA* 1974;229:1900–1902.
9. Dixon PM, Nolan DJ. The diagnosis of Meckel's diverticulum: a continuing challenge. *Clin Radiol* 1987;38:615–619.
10. Schwartz MJ, Lewis JH. Meckel's diverticulum: pitfalls in scintigraphic detection in the adult. *Am J Gastroenterol* 1984;79:611–618.
11. Treves S, Grand RJ, Eraklis AJ. Pentagastrin stimulation of technetium-99m uptake by the ectopic gastric mucosa in a Meckel's diverticulum. *Radiology* 1978;128:711–712.
12. Petrokubi RJ, Baum S, Rohrer GV. Cimetidine administration resulting in improved pertechnetate imaging of Meckel's diverticulum. *Clin Nucl Med* 1978;3:385–388.
13. Sfakianakis GN, Anderson GF, King DR, Boles ET. The effect of gastrointestinal hormones on the pertechnetate imaging of ectopic gastric mucosa in experimental Meckel's diverticulum. *J Nucl Med* 1981;22:678–683.